

## THE USE OF A SIMPLE GLASS VIAL AS A MODIFIED CONTACT PLATE FOR VIDEODERMOSCOPY OF THE EAR CONCHA

Sandip Agrawal<sup>1</sup>, Rachita Dhurat, Aseem Sharma<sup>1</sup>, Deep Jarsania,<sup>1</sup>

<sup>1</sup>Dept. of Dermatology, Lokmanya Tilak Municipal Medical College & General Hospital, Sion, Mumbai-400022

**Corresponding Author:**

Dr. Rachita Savalaram Dhurat

B 14/2, Maitri Park Society, Sion Trombay Road, Chembur, Mumbai - 400 071 • 9830790057

Email- rachita.dhurat@yahoo.co.in

Sir,

Polarized Contact dermoscopy (PCD) scores higher over polarized non-contact dermoscopy (PNCD) to visualize specific structures like shiny white streaks, crystalline areas, fine dots or peppering, to differentiate between blue and white colours and for vascular lesions.<sup>(1)</sup> Conventional contact plates that are supplied with videodermoscopes, pose a challenge to examine difficult-to-access areas like the concha of the external ear (Figure 1a&b), interdigital area and the vestibule of the mouth. These areas have irregular contours, thereby making uniform contact difficult. These plates are limited by their size, shape and financial effect. We devised the use of a simple glass vial as a contact plate to overcome this. (Figure-2a,b&c) Fig. 1a,b, 2a,b,c

**Technical Solution:** We used an empty, transparent, uncorked 1mL glass vial (injection histoglob) vial as a contact plate adapter. When inserted into the central column of the polarized video dermoscope, head first, it makes for a perfect fit, and its base serves as a contact plate. The refracted light from the surface of the contact

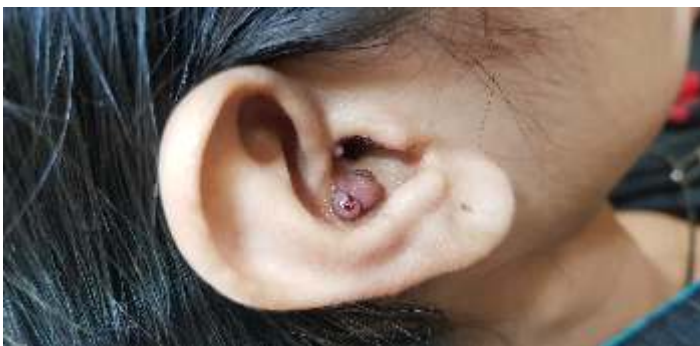plate is blocked by the polarizing filter. This assembly can be used to facilitate uniform contact with the surface, and visualize space-constrained areas, as shown in the figures. The resultant images are sharp, and the said structures are delineated, with no compromise on quality. (Figure-2d&e)

### How to cite this article:

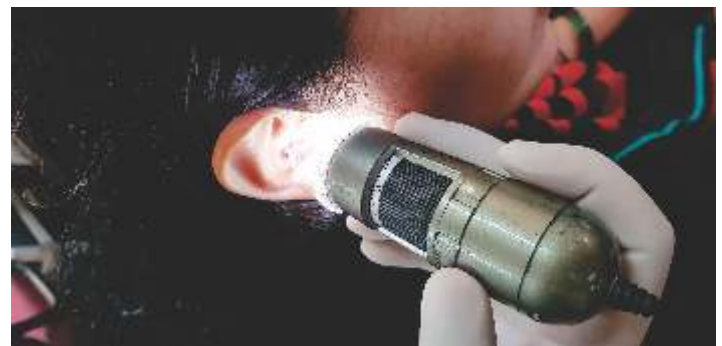Sharma S, Dhurat S, Vishwanath T, Agarwal S, Jarsania D, Sharma R. Chrysalis sign– A new dermoscopic entity in the diagnosis of angiolymphoid hyperplasia with eosinophilia. JDA Indian Journal of Clinical Dermatology 2020;3:72-73

### References

1. Benvenuto-Andrade C, Dusza S, Agero A et al. Differences Between Polarized Light Dermoscopy and Immersion Contact Dermoscopy for the Evaluation of Skin Lesions. Arch Dermatol. 2007;143(3). doi:10.1001/archderm.143.3.329



**Figure-1 (a):** A difficult-to-access area: the aural concha



**Figure-1 (b):** Inability to establish contact with the existing plate in the said area



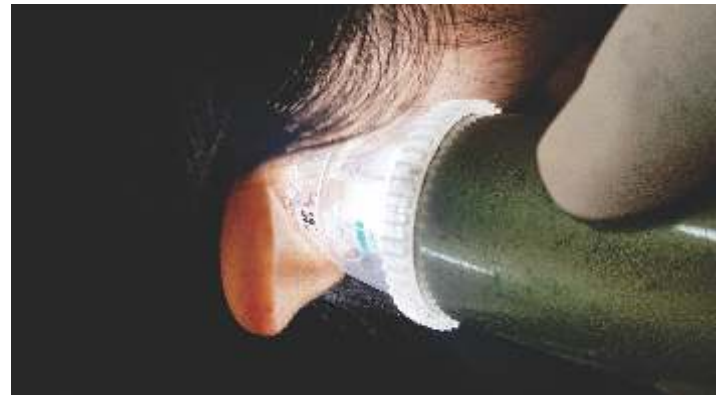**Figure-2 (a):** A difficult-to-access area: the aural concha



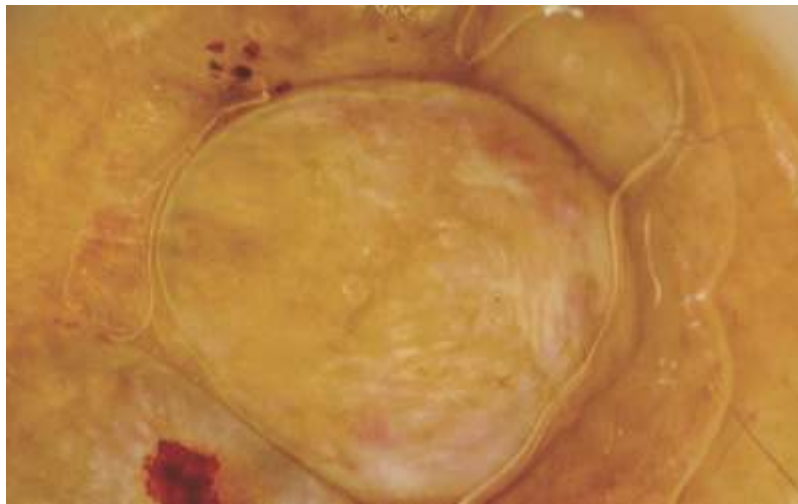
**Figure-2. (a)&(b):** A simple, transparent glass vial with the videodermoscope (c) Insertion of the said vial into the central column, making it a perfect



**Figure-1 (c):** Insertion of the said vial into the central column, making it a perfect fit



**Figure-1 (d):** Uniform contact achieved in a difficult-to-access area



**Figure-1 (e):** Sharp images, with good delineation of structures. Seen here, are lesions of angiolymphoid hyperplasia with eosinophilia with white orthogonalchrysalis-like structures over an erythematous hue.

