

## NAIL DISORDERS IN GERIATRIC AGE GROUP

Nivedita Kakkad<sup>1</sup>, Kishor Singh<sup>1</sup>

<sup>1</sup>Department of Dermatology & VL, National Institute of Medical Sciences & Research, Jaipur- 303121, Rajasthan, India.

**Corresponding Author:**

Nivedita Kakkad

Department of Dermatology & VL, National Institute of Medical Sciences & Research, Jaipur

Email: nbkakkad@gmail.com

### Abstract

**Introduction:** Nails are one of the most fascinating appendages of the epidermis. Nail disorders accounts for approximately 10% of all the dermatological conditions. With increasing age, association of chronic life style disorders increases which further enhance the chances of acquiring various nail changes. **AIM AND OBJECTIVE:** To study the physiological and pathological nail changes due to various dermatological or systemic disorders in the geriatric age group. **METHOD AND MATERIAL:** Hundred patients above the age of 60 years visiting out patient department of dermatology, venereology and leprosy of tertiary care hospital were included in the study. **OBSERVATION AND RESULT:** Among 100 patients included in the study the commonest nail change noted was onychorrhexis (97%) and the most common occupation among the study population was agriculture (50%). **CONCLUSION:** Onychorrhexis was the commonest nail change observed in 97% of patients, which is reported to be a characteristic senile nail change. Many of these nail changes had associated systemic diseases like anaemia, pulmonary diseases, cardiac dysfunction, diabetes mellitus, malnutrition, internal malignancy etc. Awareness of the signs and symptoms of nail disorder in elderly is essential for better assessment and management of the onychological concerns in geriatric age group.

**Keywords:** nail disorders, geriatric

### Introduction

Nails are one of the most fascinating appendages of the epidermis. The basic function of nail is protection, yet it serves many other important functions as well. In animals it is important for their survival, as nails play an important role in hunting, running and grasping. In human, nails provide protection to the nail bed, and may also serve as indicators for disease, aging and even provide beauty and hygiene indications. Human nails have evoked interest of researchers since time immemorable. Nail disorders includes those abnormalities that may affect any portion of the nail unit. Nail disorders accounts for approximately 10% of all the dermatological conditions and are seen more frequently in geriatric population.<sup>1,2</sup> The nail changes are more commonly observed among elderly because of the reduced oxygen supply and nutrition to the nail apparatus. With increasing age, association of chronic life style disorders like diabetes mellitus, hypertension, atherosclerosis and malnutrition increases which further enhance the chances of acquiring various nail changes.

Manual workers in industrial and agricultural sectors are at greater risk of developing nail changes because of repeated injuries at work place and exposure to hazardous chemical and inadequate nutrition. In our country, larger population is engaged in agricultural work so in these cases nail changes may be seen at an early age.

This study was conducted to analyse the physiological and pathological changes of nail in geriatric age group.

### Aims and Objectives

To study the pathological nail changes due to various

dermatological or systemic disorders in the geriatric age group as well as due to aging process.

### Material And Method

The study was carried out in the department of dermatology, venereology and leprosy at a tertiary care hospital.

In the study 100 patients above the age of 60 years were enrolled to study various nail changes.

The onset, duration and progression of nail changes and their location were recorded. A detailed history was elicited to detect various precipitating and / or alleviating factors like trauma, medications, mental and physical stress, use of cosmetics, and associated cutaneous or systemic disorders.

A careful general physical, systemic and dermatological examination was carried out and findings recorded. Relevant investigations like KOH (potassium hydroxide) mount of the nail clippings for fungus, complete haemogram, urine analysis and any other investigations whenever needed to evaluate for associated systemic diseases were carried out and nail biopsy was done in selected cases only.

### Inclusion Criteria

Patients aged more than 60 years, of both sexes, with nail changes were included in the study.

### Exclusion Criteria

Patients with nail changes due to genodermatoses, congenital disorders and unwilling patients were excluded.

### Observation And Results

One hundred consecutive patients aged above 60 years, satisfying the inclusion criteria, were drawn for the study at a tertiary care hospital in Jaipur.

**Table 1.** Age and sex distribution of patients

S. No.	Age (in years)	Male	Female	Total
1.	61 -70	58	22	80
2.	71 -80	13	07	20
3.	>80	00	00	00
	Total	71	29	100

Among 100 patients, 71(71%) were male and 29(29%) were female, with a male to female ration of 2.45:1

The age range of patients was 61-80 years. Mean age was 67.37 years.

**Table 2.** Distribution of patients by occupation

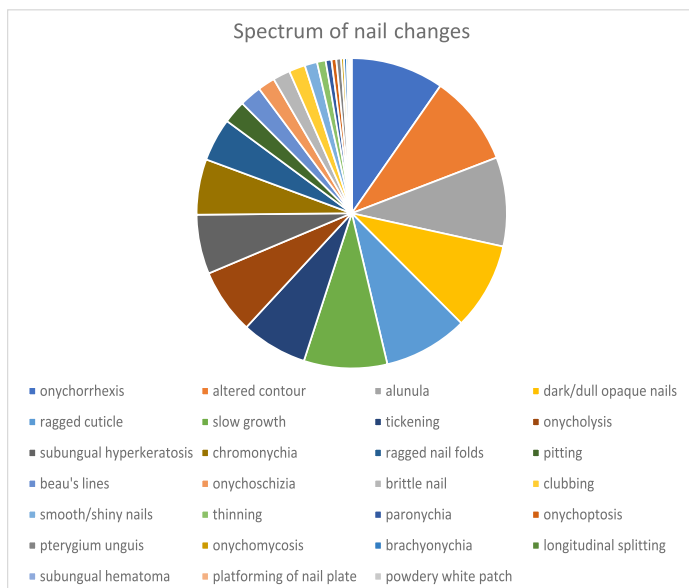
S. No.	Occupation	Male	Female	Total
1.	Agriculture	42	08	50
2.	Housewife	NA	18	18
3.	Business	13	00	13
4.	Retired teacher	07	03	10
5.	Coolie	02	00	02
6.	Potter	01	00	01
7.	Basket weaver	01	00	01
8.	Office work	01	00	01
9.	Others	04	00	04
	Total	71	29	100

The most common occupation among the study population was agriculture(50%), followed by housewife (18%), business (13%), retired teacher(10%), coolie (2%), office worker (1%), potter (1%), basket weaving work (1%) and other (4%).

The duration of nail disorders ranged from 3 months to 30 years with an average of 4.68 years.

History of varying degree of repeated trauma to nail or surrounding area was present in 73 patients out of which 56 were male and 17 were female.

Spectrum of nail changes:



The spectrum of nail changes in the 100 patients included in the study is shown in Fig 1. The commonest nail change noted was onychorrhexis (97%). Other nail changes in decreasing order were altered contour (95%), Alunula (93%), dark/dull opaque

nail (91%), ragged cuticle (88%), slowing of nail growth rate (87%), thickened nail plate (69%), onycholysis (68%), subungual hyperkeratosis (62%). Chromonychia (58%), ragged nail folds (45%), pitting (24%), Beau's lines (23%), onychoschizia (18%), brittle nails (18%), clubbing (17%), thinning of nail plate(9%), smooth shiny nails (7%), paronychia(6%), onychoptosis (5%), pterygium unguis (5%), onychomycosis (3%), brachyonychia(3%), longitudinal splitting (2%), subungual hematoma (1%), platforming of nail plate (1%), and powdery white patch (1%).

Many of these nail changes were associated with systemic/ dermatological manifestation as shown in table 3.

**Table 3.** Systemic/ dermatological association of nail changes

S. No.	Nail changes	No. of cases	Associated Disease
1.	Koilonychia and platonychia	48	Anemia, coronary disease, clay work
2.	Onycholysis	43	Anemia, leprosy, psoriasis, palmo-plantar keratoderma
3.	Pitting	16	Psoriasis, alopecia areata, paronychia, leprosy, dermatitis
4.	Subungual hyperkeratosis	12	Psoriasis, leprosy, palmo-plantar keratoderma
5.	Beau's lines	08	Fever with cellulitis, COPD, carcinoma breast on radiotherapy, contact dermatitis, stroke, trauma
6.	Clubbing	08	COPD, HTN, Congestive cardiac failure, carcinoma, malnutrition
7.	Terry's nails	06	Type 2 DM, congestive cardiac failure, pleural effusion, stroke
8.	Longitudinal melanonychia	06	Cnacer chemotherapy –cisplatin, 5FU, cyclophosphamide, Adriamycin
9.	Thinning	05	Anemia
10.	Diffuse chromonychia	05	Diabetes, Malnutrition, anemia, radiotherapy, leprosy
11.	Transverse chromonychia	03	Cancer chemotherapy –5FU, cyclophosphamide, Adriamycin
12.	Half and half nails	02	Carcinoma breast, supraglottic carcinoma

## Discussion

In the present study carried out at a tertiary care hospital in Jaipur sixty years was taken as cut off age for defining geriatric age group as per health statistics and information system of WHO.<sup>3</sup>

Among the 100 patients, 71% were male and 29% were female, showing strong male preponderance. However no significant difference in sex distribution of nail disorders was noted by a study conducted by committee for care of nail disorder of American Academy of dermatology(Drake LA).<sup>2</sup>

History of varying degree of trauma was present in 73% patients making it one of the most common aetiological factors for nail changes in elderly which is consistent with study conducted by Drake LA.<sup>2</sup>

In our study onychocorrhexis (longitudinal ridging and beading) was the commonest nail change, observed in as many as 97% of patients. Old age was reported to be the commonest cause of onychorrhexis in a study by Holzberg M (2000).<sup>4</sup>

Altered contour of nail plate in the form of platyonychia, koilonychia, increased transverse curvature, pincer nails, irregular dystrophic nail plate and downward bending of nail plate was also present in 95% of cases in our study.

A Study by Baran R et al(1994) on nail in childhood and old age, Cohen PR et al (2000), Dawber R et al (2001), and Kusher D. med surg (1992) have reported similar nail changes in elderly age group.<sup>5,6,7,8</sup>

Paronychia was commonly associated with ragged cuticle<sup>9</sup>, and in our study observed among agricultural workers and manual workers including housewives.

History of slowing of nail growth rate was present in 87% of cases with slightly higher prevalence (89%) in patients aged 71-80 years.

Dark, dull opaque nails were seen in high proportion (91%) of cases, which is yet another important sign of senility of the nails.<sup>6</sup> Absence of lunula was found in 93% of our patients. It is reported to be an important senile nail change by various workers in their study done by Lewis BL (1995) and Cohen PR (1996).<sup>10,11</sup>

Terry's nail was observed in a total of 13 cases, 6 of these were associated with systemic illness whereas 7 others had no associated disorder. These cases had Terry's nail presumably due to aging process itself.

One case of half and half nails was documented. This nail condition is commonly observed in patients with uraemia<sup>12</sup> however in our study it was associated with carcinoma of breast.

Neapolitan nail is reported as a characteristic nail change occurring in the elderly<sup>1</sup>. This uncommon change was seen in only 1 patient in our study.

Diffuse/ partial brownish or brownish black chromonychia was observed in our study in 39 patients. Chromonychia as observed in our study is associated with malnutrition, anaemia, vitamin B12 deficiency and in some cases with aging process itself.

Nixon DW (1976) reported longitudinal and transverse melanonychia after cancer chemotherapy<sup>13</sup>. Similar changes were seen in 3 patients in our study.

Radiotherapy given elsewhere on body is also known to cause brownish chromonychia<sup>14</sup>, which was observed in 1 patient in this study. Similar results have been reported in a study by Baran R et al (1994). Longitudinal melanonychia can also be seen normally in blacks and Indians<sup>14</sup>, and was seen in 2 of our patients.

Thickened nail plate in the form of onychauxis (35 patients), pachyonychia (18), hemionychogryphosis (10) and onychogryphosis (6 patients) were observed as a manifestation of aging in our study.

On the other hand, 9 patients had thinning of nail plate. 15 Anaemia was present in 5 of these patients. Similar results have been reported in study conducted by Baran R, Dawber RPR (1994).<sup>14</sup>

Onycholysis was recorded in 68 patients in our study out of which 47 were male and 21 were female. It was associated with many systemic and dermatological diseases like anaemia, psoriasis, palmoplantar keratoderma and leprosy.

Subungual hyperkeratosis was present in 62 patients in our study out of which 46 were male and 16 were female. It was associated with psoriasis in 10 patients, leprosy and palmoplantar keratoderma in 1 patient each.

Though combination of onycholysis, subungual hyperkeratosis, brittle nail and chromonychia indicates possibility of onychomycosis, in our study only 3 patients were found to be KOH positive. This implies that these changes may largely be part of aging process.

Nail pitting was seen in 24 patients, of which 8 were probably due to ageing process while the rest had associated dermatological conditions like psoriasis, alopecia areata, atopic dermatitis etc.

Beau's lines were noticed in 23 patients in our study out of which 17 were male and 6 were female. All of these cases were associated with underlying dermatological or systemic diseases.

Onychoschizia and brittle nails were found in 18 patients. This high prevalence appears to be due to prolonged and repeated cycle of hydration and dehydration, as majority of patients were involved in occupation like agriculture, housewife and potter.<sup>16,17</sup>

Clubbing was present in 17 patients in our study out of which 11 were male and 6 were female.

Other nail changes presumably due to ageing seen in our study were smooth shiny nails (13 patients), brachyonychia (2 patients), longitudinal splitting (1 patient), pterygium unguis (1 patient), flattening of nail plate (1 patient), superficial powdery white patches of nail plate (1 patient), trauma induces onychoptosis (5 patients) and subungual hematoma in 1 patient.

### Conclusion

Onychorrhexis was the commonest nail change observed in 97% of patients, which is reported to be a characteristic senile nail change. Other such senile changes seen in our study were altered contour (95%), lunula (93%), dark/dull opaque nail (91%), ragged cuticle (88%), slowing of nail growth rate (87%), thickened nail plate (69%), onycholysis (68%), subungual hyperkeratosis (62%). Chromonychia (58%), ragged nail folds (45%), pitting (24%), beau's lines (23%), onychoschizia (18%), brittle nails (18%), clubbing (17%), thinning of nail plate (9%), smooth shiny nails (7%), paronychia (6%), onychoptosis (5%), pterygium unguis (5%), onychomycosis (3%), brachyonychia (3%), longitudinal splitting (2%), subungual hematoma (1%), platforming of nail plate (1%), and powdery white patch (1%).

Many of these nail changes had associated systemic diseases like anaemia, pulmonary diseases, cardiac dysfunction, diabetes mellitus, malnutrition, internal malignancy etc.

Cutaneous disorders associated with nail changes were psoriasis, lichen planus, alopecia areata, paronychia, palmoplantar keratoderma, eczema and leprosy etc.

Awareness of the signs and symptoms of nail disorder in elderly is essential for better assessment and management of the onychological concerns in geriatric age group.

### How to cite this article:

Kakkad N, Singh K. Nail Disorders In Geriatric Age Group. JDA Indian Journal of Clinical Dermatology 2020;3:31-34

### References

1. Raja babu KK. Nail and its disorders. In: Valia RG, Valia AR, Bajaj AK, Ganapati R, Girdhar BK, Haldar B et al. editors. IADVL Textbook and atlas of Dermatology. 2nd ed. Mumbai: Bhalani Publishing House, 2001.p.763-98.
2. Drake LA, Dinehart SM, Farmer ER, Goltz RW, Graham GF, Hordinsky MK, et al. Guidelines of care for nail disorders. J Am Acad Dermatol. 1996;34:529-33.
3. Orimo, Hajime & Ito, Hideki & Suzuki, Takao & Araki, Atsushi & Hosoi, Takayuki & Sawabe, Motoji. (2006). Reviewing the definition of "elderly". Geriatrics and Gerontology International. 6. 10.1111/j.1447-0594.2006.00341.x.
4. Holzberg M. Nail signs of systemic disease. In: Hordinsky MK, Sawaya ME, Scher RK. Editors. Atlas of hair and nails. Philadelphia: Churchill Livingstone; 2000.p. 59-70.
5. Baran R, Dawber RPR. The nail in childhood and old age. In: Baran R, Dawber RPR, editors. Disease of the nails and their management. 2nd ed.

- Oxford: Blackwell Scientific Publications; 1994.p.81-96
6. Cohen PR, Scher RK. Aging. In: Hordinsky MK, Sawaya ME, Scher RK, editors. Atlas of hair and nails. Philadelphia: Churchill Livingstone; 2000.p.213-35
  7. Dawber R, Bristow I, Turner W. Nail Disorders. In: Text atlas of podiatric dermatology. London: Martin MartinDunitz Ltd; 2001.p.105-31
  8. Kushner D. Primary podiatric care of the vascularly compromised patient. Clin podiatric Med Surg. 1992;9:109-23
  9. Rich P. Nail disorders: diagnosis and treatment of infectious, inflammatory and neoplastic nail conditions. Med Clin North Am. 1998;82:1171-83.
  10. Lewis BL, Mantgomery H. The senile nail. J Invest Dermatol. 1955; 24:11-8.
  11. Cohen PR. The lunula. J Am Acad Dermatol. 1996;34:943-53.
  12. Lindsay PG. The half-and-half nail. Arch Intern Med. 1967;583-7.
  13. Nixom DW. Alterations in nail pigment with cancer chemotherapy. Arch Intern Med. 1976;136:1117-8.
  14. Baran R, Dawber RPR. Physical signs. In: Baran R, Dawber RPR, editors. Diseases of nails and their management. 2nd ed. Oxford: Blackwell Science; 1994.p.35-80.
  15. Dawber RPR, Baran R. Structure embryology comparative anatomy and physiology of the nail. In: Baran R, Dawber RPR, editors. Diseases of the nail and their management. 2nd ed. Oxford: Blackwell scientific publications;1994.p.1-34.
  16. Scher RK. Brittle nails. Int J Dermatol 1989;28:515-6.
  17. Wallis MS, Bowen WR, Guin JD. Pathogenesis of onychoschizia (lamellar dystrophy). J Am Acad Dermatol. 1991;24:44-8.

