

THE DERMOSCOPIC CONSTELLATION OF BASAL CELL CARCINOMA

Aseem Sharma¹, Sandip Agrawal¹, Deep Jarsania¹, Kiran Chahal¹, Rachita Dhurat¹

¹ Dermatology Department, Lokmanya Tilak Municipal Medical College & General Hospital, Sion, Mumbai – 22

Corresponding Author:

Dr Aseem Sharma

Assistant Professor (Dermatology), OPD 16, Department of Dermatology, LTM General Hospital, Sion, Mumbai – 400022

E-mail – aseemsharma082@gmail.com

Abstract

When it comes to basal cell carcinoma (BCC), dermoscopy is primarily a diagnostic aid, helping in its discrimination from other cutaneous tumours and morphologically similar dermatoses. It also has a role in subtyping, since it provides clinicopathological correlation, especially in pigmented BCC. And lastly, its role as a prognosticator, by assessing the extension of the tumour beyond clinically visible margins, and by gauging the response to various non-ablative treatments in follow-up visits. The dermoscopic compendium and diagnostic criteria for basal cell carcinoma (BCC) have been described in global literature, over the last two decades. We report a case, wherein, all eleven diagnostic criteria were found in a single dermoscopic frame. This can be helpful for teaching purposes and educational demonstrations.

Key words: basal cell carcinoma, dermoscopy, dermatoscopy, diagnosis

Sir,

A 59-year-old woman presented to the dermatology department with the chief complaint of a black facial patch, of 7 months' duration, which had increased in size, and begun bleeding, spontaneously, over the course of the past 5 weeks. Cutaneous examination revealed a solitary, well-circumscribed hyperpigmented (black to brown) plaque measuring 4 cm over

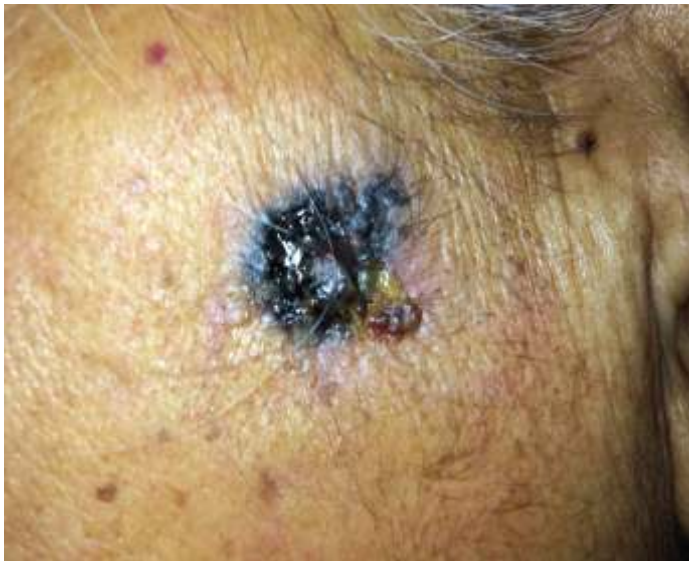

Figure 1: A solitary, hyperpigmented plaque, 4 x 2.5 cm, over left zygomatic region. Ulceration, erosions, serosanguinous crusting can be appreciated.

the widest axis and 2.5 cm on the short axis, over the left zygomatic region. (Figure-1) Ulceration, erosions and serosanguinous crusting were noted at 4 o' clock position of the lesion. No regional lymphadenopathy was noted on general

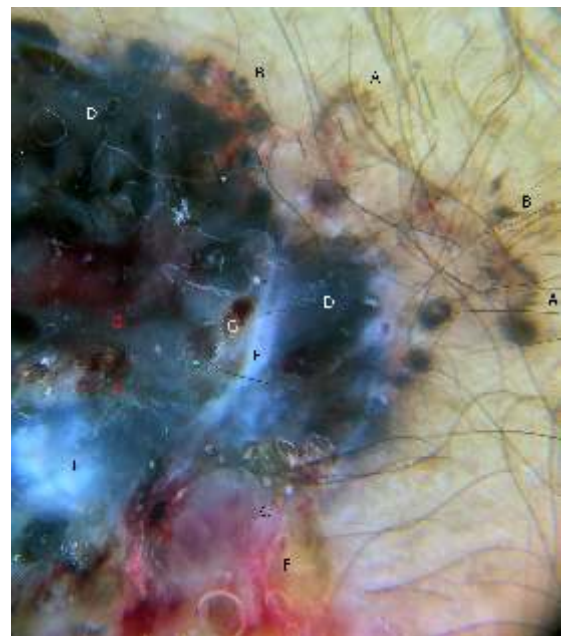


Figure 2: Polarized dermoscopy: A - spoke-wheel structures, B – maple-leaf structures, C – pinkish-white background, D - blue-gray-ovoid clods, globules and blotches, E–amorphous crystalline areas, short white lines, white blotches, F – arborizing telangiectasia and atypical vessels, G – ulceration, frank hemorrhage and red dots

examination. Contact polarized dermoscopy, with an immersion fluid, was performed, which revealed findings of: blue-gray-ovoid clods and globules, pigmented maple-leaf and spoke-wheel structures, a pinkish-white backdrop, short white chrysaloid lines, white amorphous areas, ulceration, erosions and atypical vasculature in the form of arborizing telangiectasia, red dots and areas of hemorrhage. (Figure-2) The dermoscopic

Table-1. The dermoscopic features described and seen in our figure have been tabulated

S. No	Dermoscopic Variables 1
1	Blue-gray ovoid nests
2	Spoke-wheel areas
3	Maple leaf-like
4	Multiple blue-gray globules
5	Ulceration
6	Short fine superficial telangiectasias
7	Arborizing vessels
8	Shiny white-red structureless areas
9	Multiple in-focus blue-gray dots
10	Concentric structures
11	Multiple small erosions

features described [1], and seen in our figure, have been tabulated as Table-1. A clinical and dermoscopic diagnosis of

pigmented basal cell carcinoma was made. A 4-mm punch biopsy from the edge of the lesion showed basaloid cell nests with peripheral palisading, and a few stromal retraction artefacts, all consistent with the clinical diagnosis. A multi-disciplinary approach was initiated, and still on follow-up and close monitoring. This case shows all the dermoscopic signs that have been reported in BCC, in one single picture, and re-emphasizes the role of the elementary, handy dermatoscope in a

How to cite this article:

Sharma A, Agarwal S, Jasrania D, Chahal K, Dhurat R. The dermoscopic constellation of basal cell carcinoma. *JDA Indian Journal of Clinical Dermatology*. 2019;2:84-85.

dermatological setup

Reference

1. Lallas A, Apalla Z, Argenziano G, et al. The dermoscopic universe of basal cell carcinoma. *Dermatol Pract Concept*. 2014;4(3):11-24. doi:10.5826/dpc.0403a02

