

TRICHOSCOPIC FINDINGS IN VARIOUS SCALP ALOPECIAS

Rahul Sharma¹

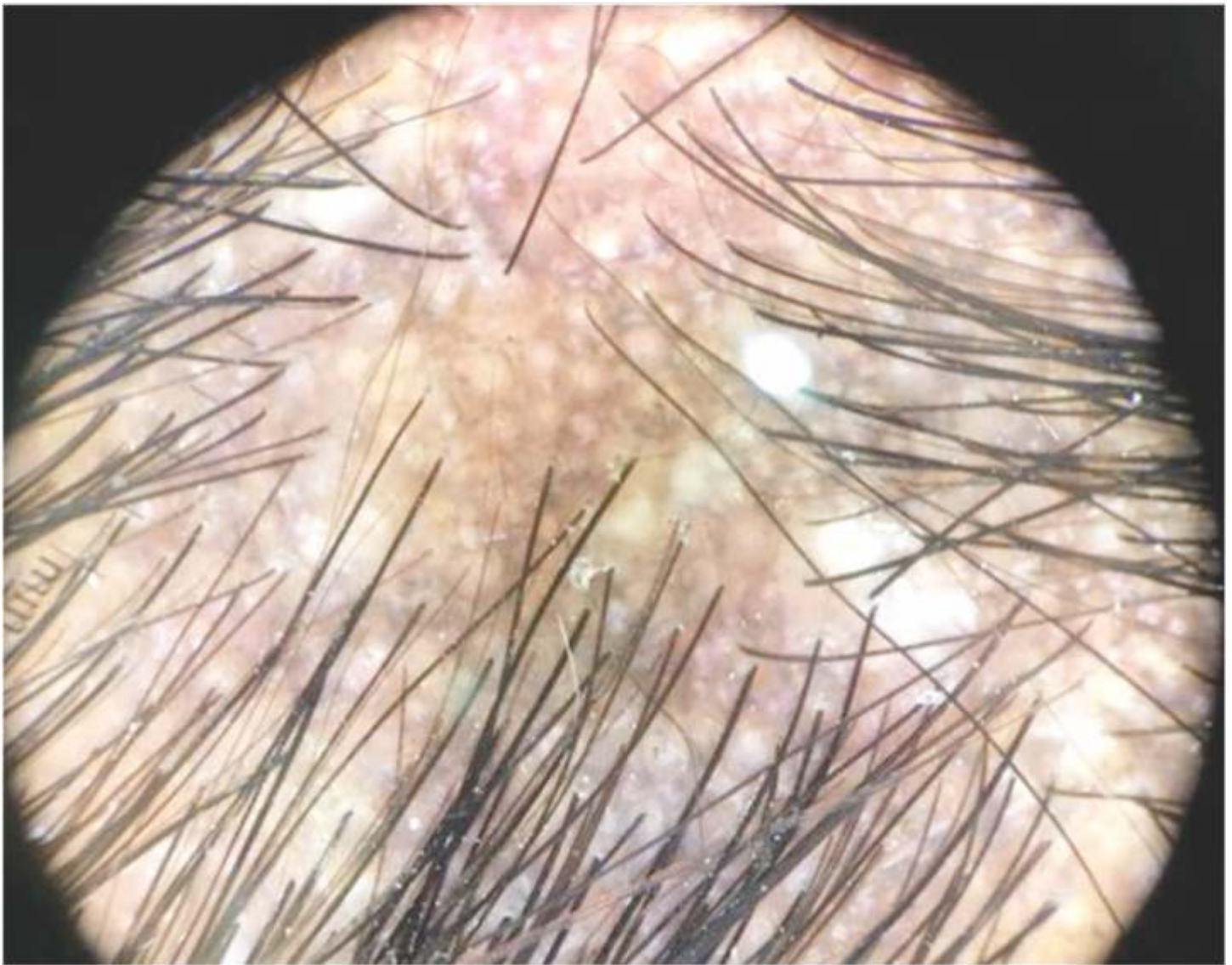
¹ Consultant dermatologist

Correspondence Address:

Dr. Rahul Kumar Sharma

Consultant dermatologist, Ajmer.

Email: consultantdermatologistmd@gmail.com



Question

This is the dermoscopic picture of cicatricial alopecia. What is the classical sign seen in the picture and what is the final diagnosis?

(For answer visit PG Quiz section at www.e-ijcd.in)